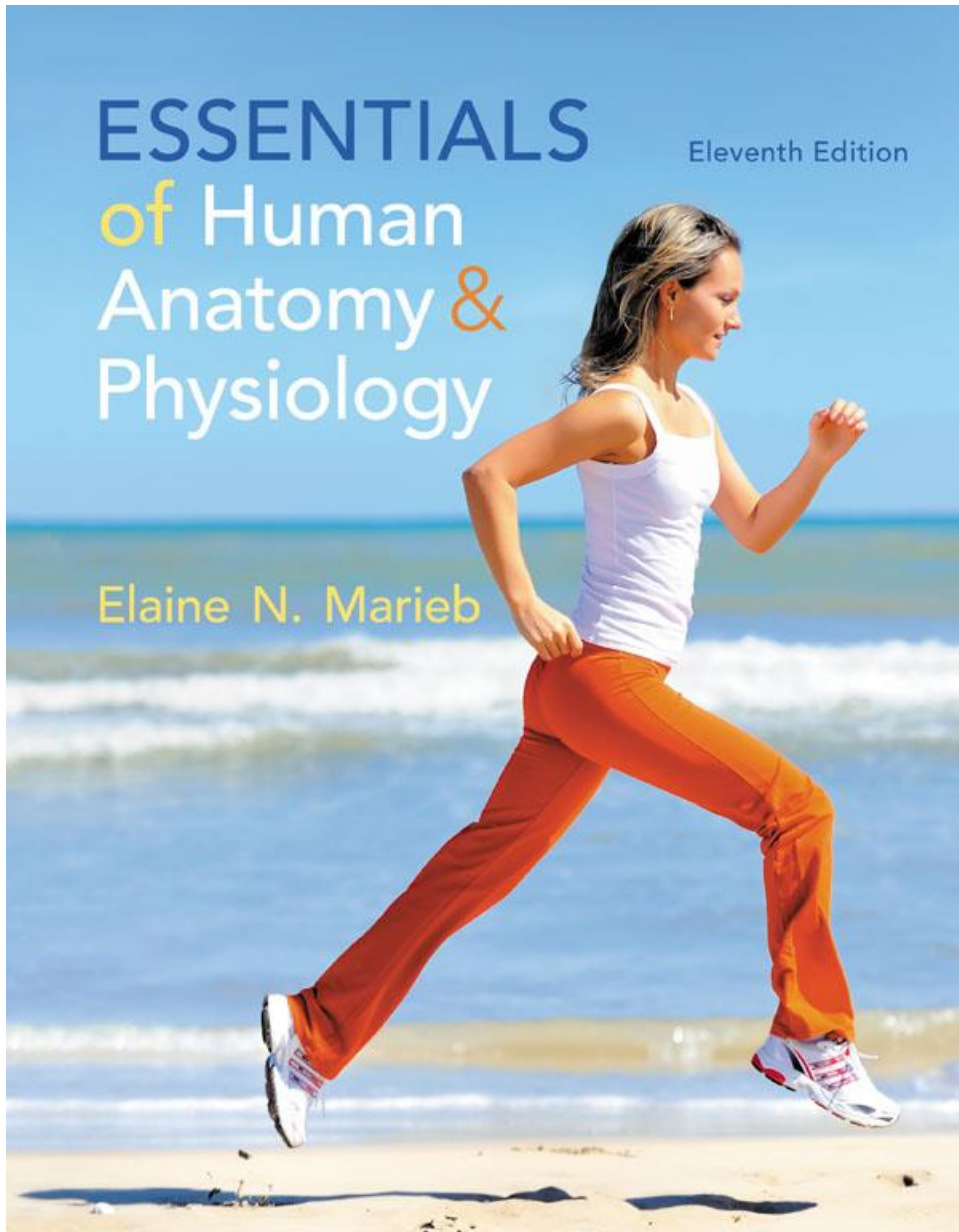

Chapter 5

The Skeletal System

Lecture Presentation by
Patty Bostwick-Taylor
Florence-Darlington Technical College

Vertebral Column (Spine)

- Vertebral column provides axial support
 - Extends from skull to the pelvis
- 26 single vertebral bones are separated by intervertebral discs
 - 7 cervical vertebrae are in the neck
 - 12 thoracic vertebrae are in the chest region
 - 5 lumbar vertebrae are associated with the lower back

Vertebral Column (Spine)

- 9 vertebrae fuse to form two composite bones
 - Sacrum formed by the fusion of 5 vertebrae
 - Coccyx (tailbone) formed by the fusion of 3 to 5 vertebrae

Figure 5.16 The vertebral column.

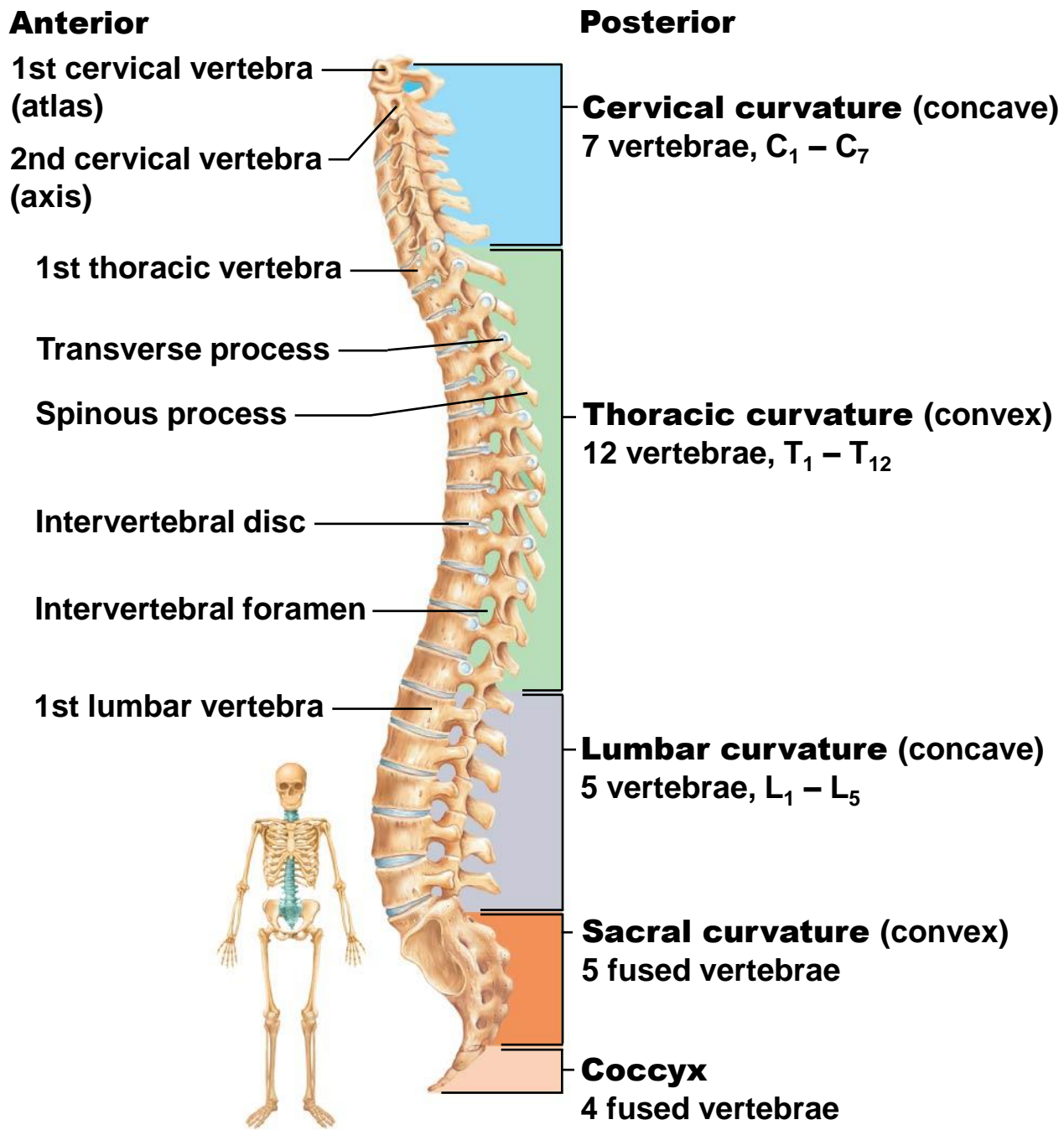
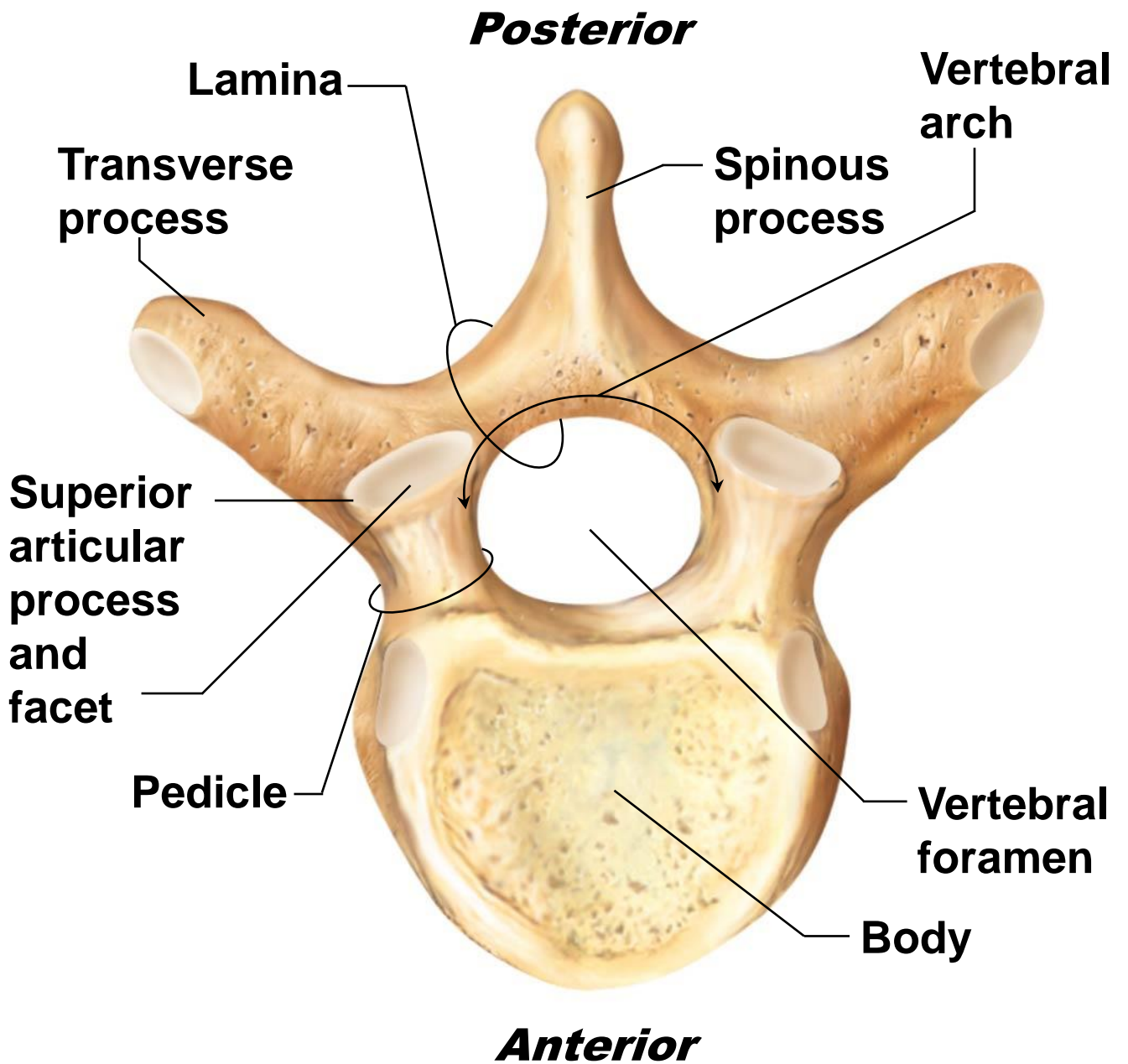
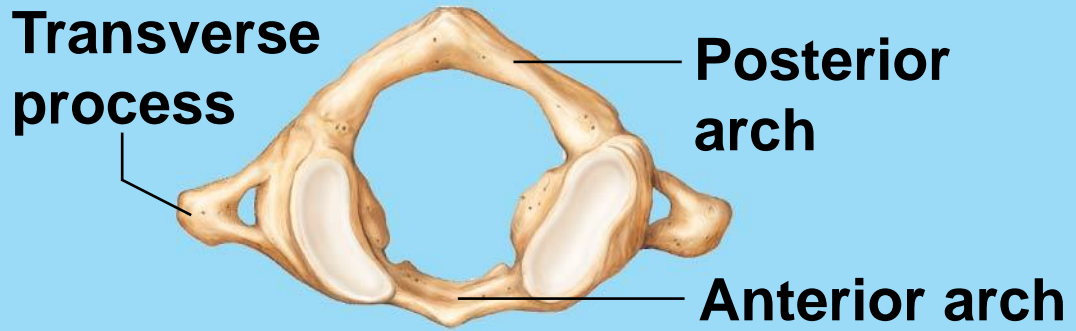


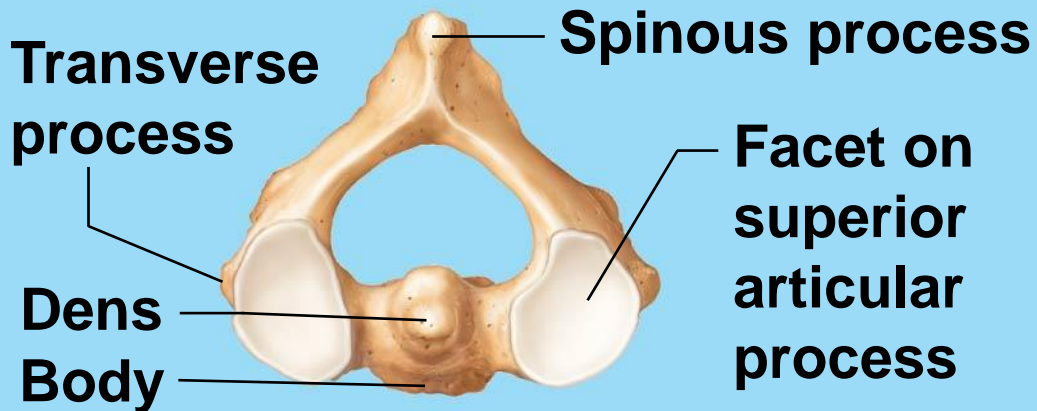
Figure 5.19 A typical vertebra, superior view.



(a) ATLAS AND AXIS



Superior view of atlas (C₁)



Superior view of axis (C₂)

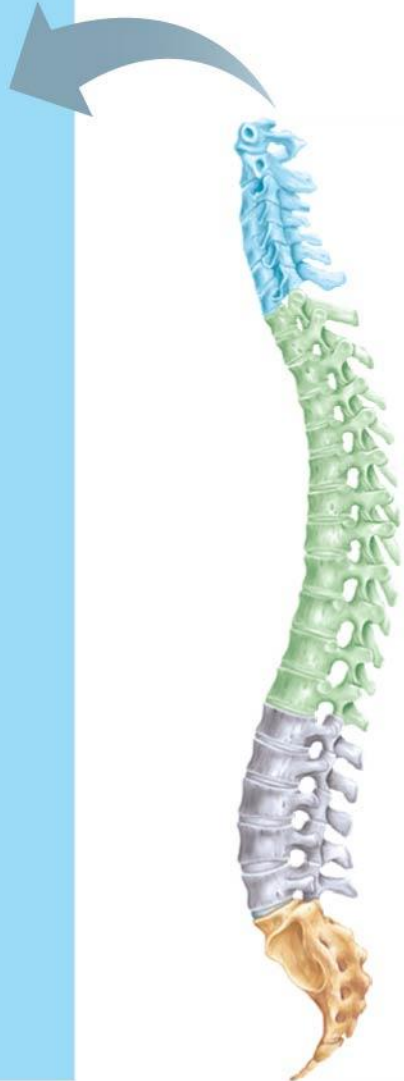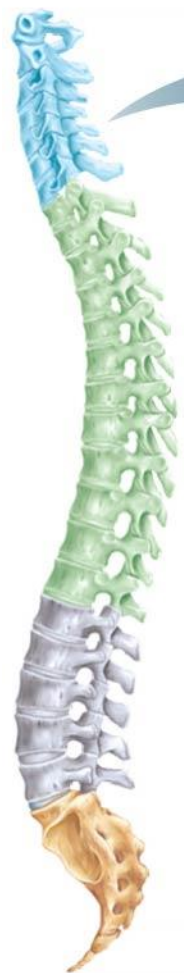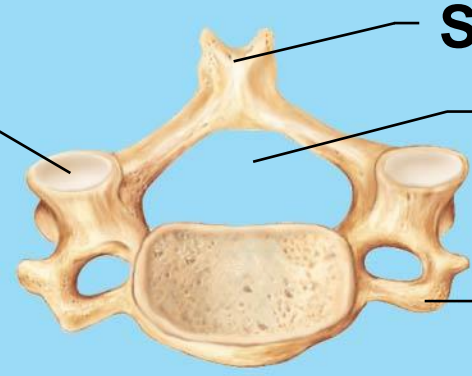


Figure 5.20b Regional characteristics of vertebrae.



(b) TYPICAL CERVICAL VERTEBRAE

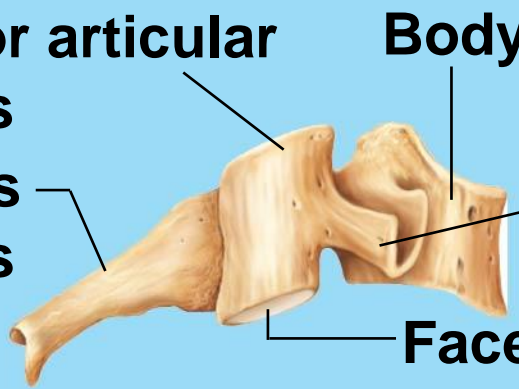
Facet on superior articular process



Spinous process
Vertebral foramen
Transverse process

Superior view

Superior articular process
Spinous process

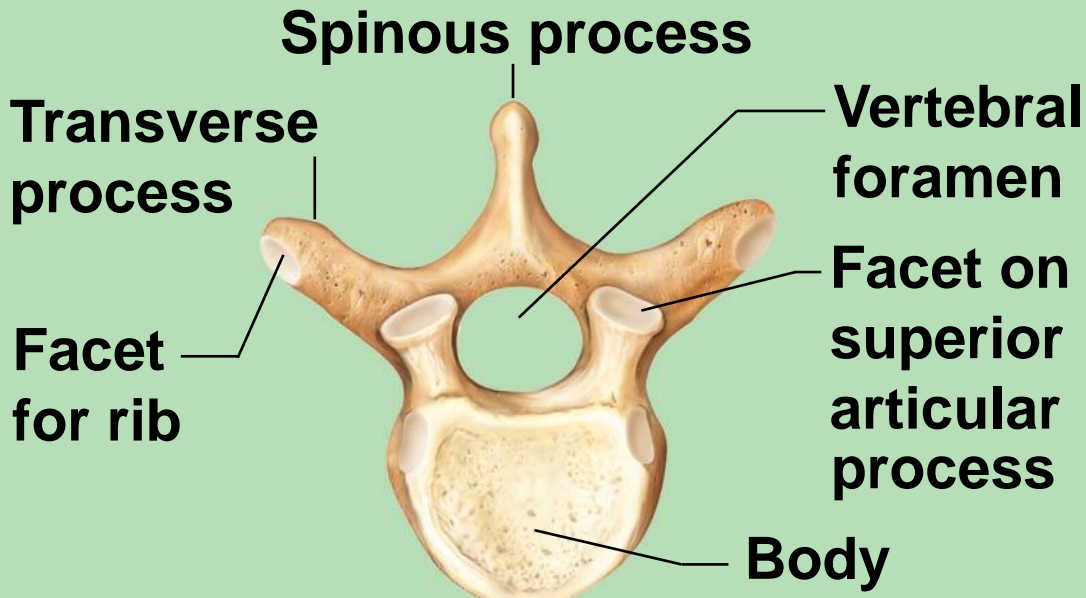


Body
Transverse process
Facet on inferior articular process

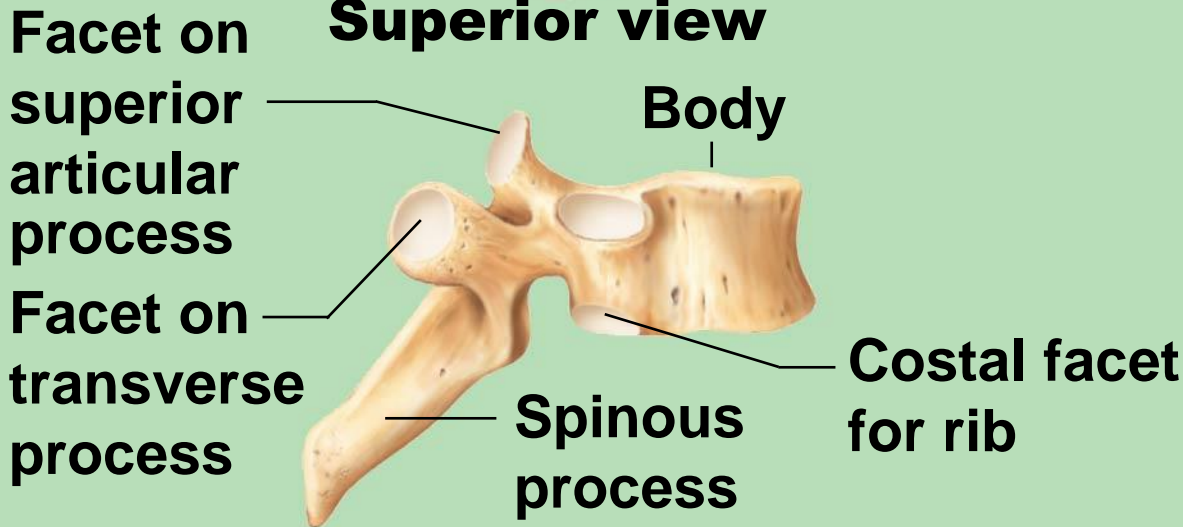
Right lateral view

Figure 5.20c Regional characteristics of vertebrae.

(c) THORACIC VERTEBRAE



Superior view



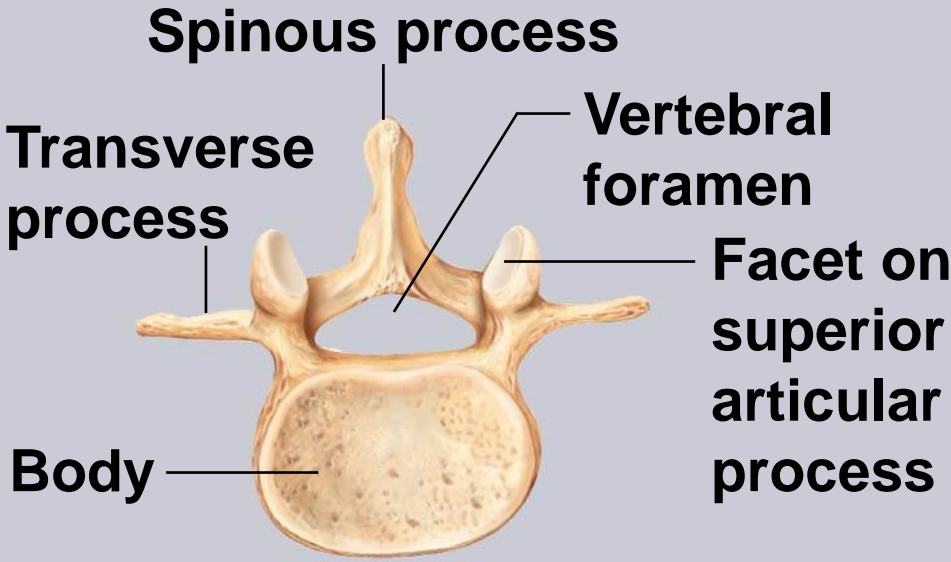
Right lateral view

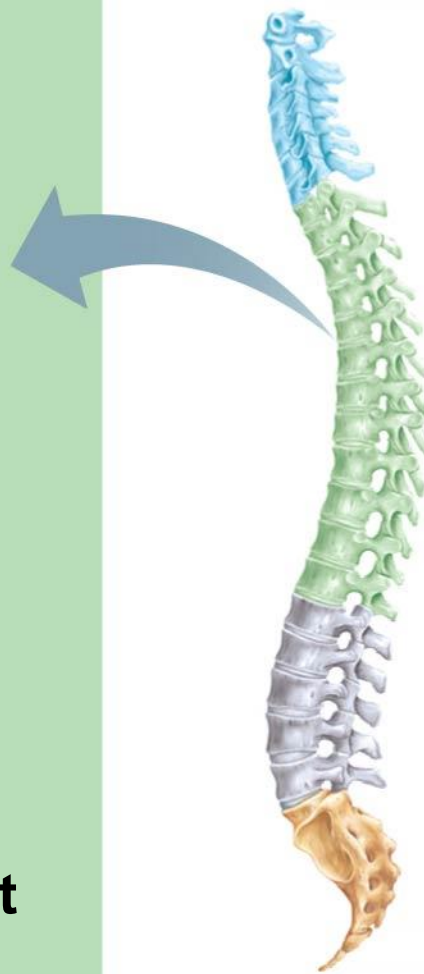
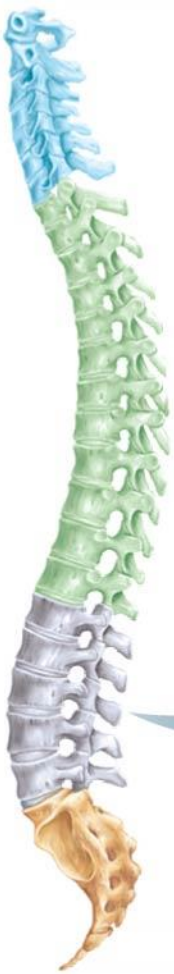
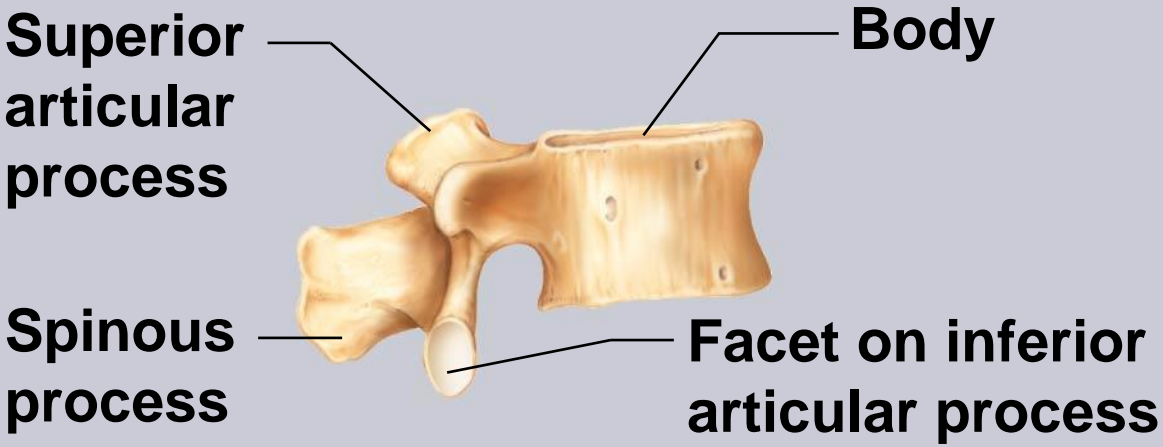
Figure 5.20d Regional characteristics of vertebrae.



(d) LUMBAR VERTEBRAE

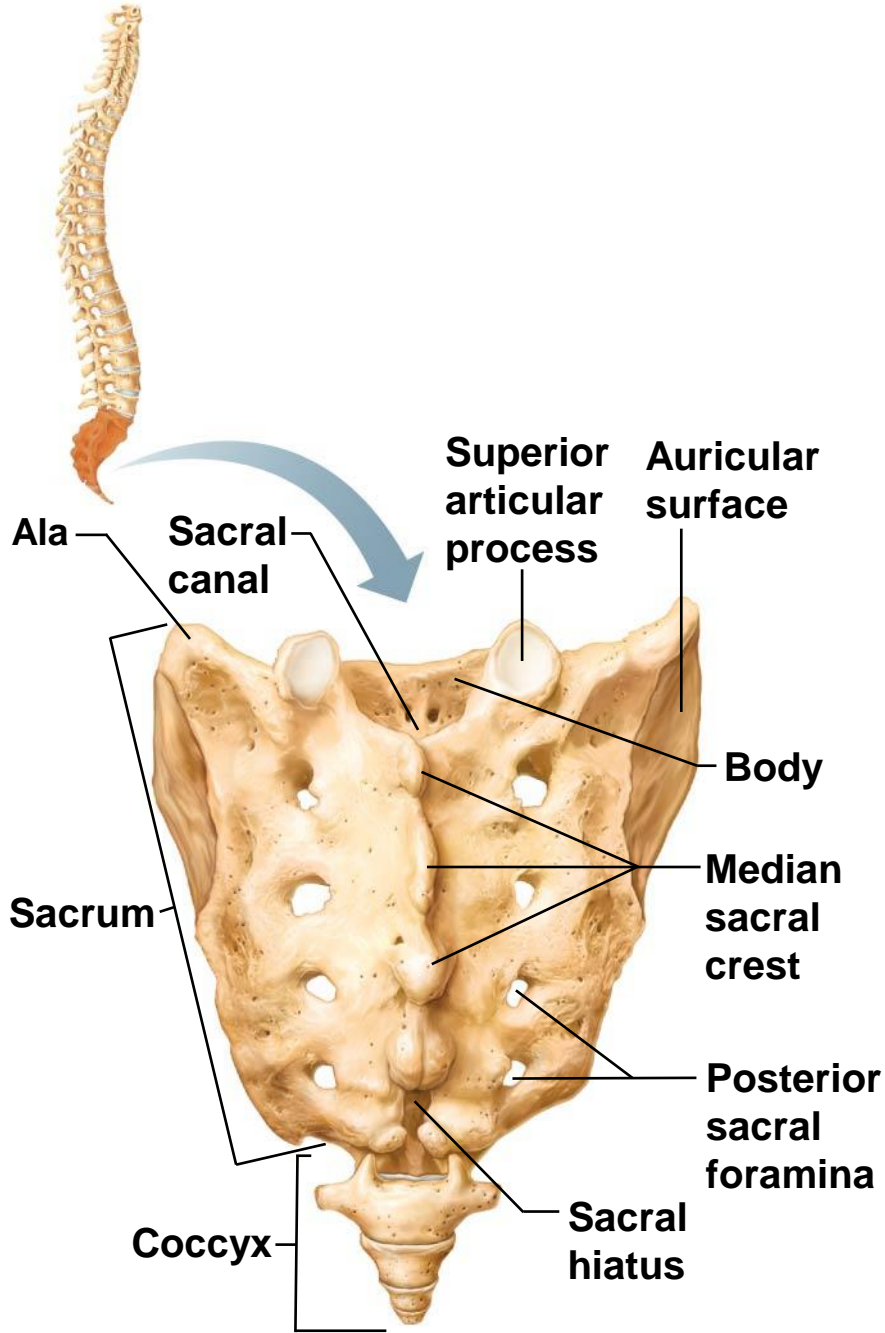


Superior view



Right lateral view

Figure 5.21 Sacrum and coccyx, posterior view.



The Bony Thorax

- Forms a cage to protect major organs
- Consists of three parts
 1. Sternum
 2. Ribs
 - True ribs (pairs 1–7)
 - False ribs (pairs 8–12)
 - Floating ribs (pairs 11–12)
 3. Thoracic vertebrae

Figure 5.22a The bony thorax (thoracic cage).

